

Generic Contrast Agents

Our portfolio is growing to serve you better. Now you have a *choice*.



[VIEW CATALOG](#)

AJNR

CT-Guided Epidural Contrast Injection for the Identification of Dural Defects

Ian T. Mark, Michael Oien, John Benson, Jared Verdoorn, Ben Johnson-Tesch, D.K. Kim, Jeremy Cutsforth-Gregory and Ajay A. Madhavan

This information is current as of May 12, 2025.

AJNR Am J Neuroradiol 2025, 46 (1) 207-210

doi: <https://doi.org/10.3174/ajnr.A8437>

<http://www.ajnr.org/content/46/1/207>

CT-Guided Epidural Contrast Injection for the Identification of Dural Defects

 Ian T. Mark,  Michael Oien,  John Benson,  Jared Verdoorn, Ben Johnson-Tesch,  D.K. Kim,  Jeremy Cutsforth-Gregory, and  Ajay A. Madhavan



ABSTRACT

SUMMARY: Post–dural puncture headache is an increasingly recognized cause of chronic headache. Outside of clinical history and myelography that requires an additional dural puncture, there is no reliable diagnostic test to evaluate for persistent dural defects. We describe the injection of iodinated contrast into the dorsal epidural space under CT guidance in 5 patients as a potential tool to visualize persistent dural defects.

ABBREVIATIONS: DSM = digital subtraction myelography; PDPH = Post–dural puncture headache; SIH = spontaneous intracranial hypotension

Spinal CSF leaks causing spontaneous intracranial hypotension (SIH) classically present with orthostatic headaches, but they can also present with nonspecific symptoms such as neck pain, tinnitus, dizziness, and behavioral changes mimicking dementia.¹ Chronic leaks present more often with atypical symptoms, which can further complicate the diagnosis.^{2,3} Post–dural puncture headache (PDPH) is an increasingly recognized cause of chronic headaches.⁴ PDPH can occur in the setting of intentional dural puncture for a diagnostic lumbar puncture⁵ or unintended dural breach during epidural catheter placement. When the latter occurs, headache becomes chronic and debilitating in 30% of cases and may persist for longer than a year.^{6,7} One paper found that the 92.6% of PDPH cases have a reported normal brain MRI and 70.4% did not have orthostatic headaches.⁸ The atypical clinical presentation and insensitivity of brain MRI, and yet debilitating symptoms, underscore the need for better diagnostic tools to confirm PDPH.

Digital subtraction myelography (DSM) has previously been described as a technique to diagnose PDPH.⁹ This technique, as with CT myelography, relies on a new dural puncture for the administration of intrathecal contrast to identify the underlying dural defect. The purpose of this report is to describe CT-guided contrast injection into the epidural space as an alternative technique to definitively confirm a dural defect without additional dural puncture.

CASE SERIES

Our institution is a high-volume treatment center for spinal CSF leak, and our practice routinely performs targeted and nontargeted blood patches under CT guidance. For each blood patch, we inject iodinated contrast into the epidural space immediately before injecting the autologous blood in a sterile manner. This technique involves advancing a needle, most often a 20- or 22-gauge Tuohy, into the dorsal epidural space via an interlaminar approach. Iodinated contrast is injected to confirm correct needle tip position in the epidural space. Our practice most commonly uses diluted contrast (1:2–3 Omnipaque-300 to sterile saline) and injects approximately 1 to 2 mL per spinal level at which blood is to be placed. CT fluoroscopy is performed immediately after the injection of contrast to look for egress into the subarachnoid space, thus identifying a persistent dural defect.


Dural Defect Case 1

A 29-year-old man with Marfan syndrome had a fluoroscopic-guided lumbar drain placed by using a 14-gauge Touhy needle at L4–L5 in the setting of endovascular aortic aneurysm repair. One day after lumbar drain removal, the patient reported new-onset headache (not further characterized) and emesis. The patient did not have a spine or brain MRI to evaluate for findings associated with spinal CSF leaks. An image-guided targeted epidural blood patch was ordered. As part of the procedure, a 20-gauge Tuohy needle was placed into the dorsal epidural space at L4–L5. Approximately 1 mL of dilute iodinated contrast was injected in the epidural space that demonstrated an immediate jet of contrast through the dural defect into the subarachnoid space (Fig 1). A targeted epidural blood patch was performed at this level, after which the patient had improvement of headaches and emesis.

Received June 11, 2024; accepted after revision July 26.

From the Departments of Radiology (I.T.M., M.O., J.B., J.V., B.J.-T., D.K.K., A.A.M.) and Neurology (J.C.-G.), Mayo Clinic, Rochester, Minnesota.

Please address correspondence to Ian T. Mark, Department of Radiology, Mayo Building, 2-50W, Rochester, MN 55905; e-mail: Mark.Ian@mayo.edu; @IanTMark

 Indicates open access to non-subscribers at www.ajnr.org

<http://dx.doi.org/10.3174/ajnr.A8437>

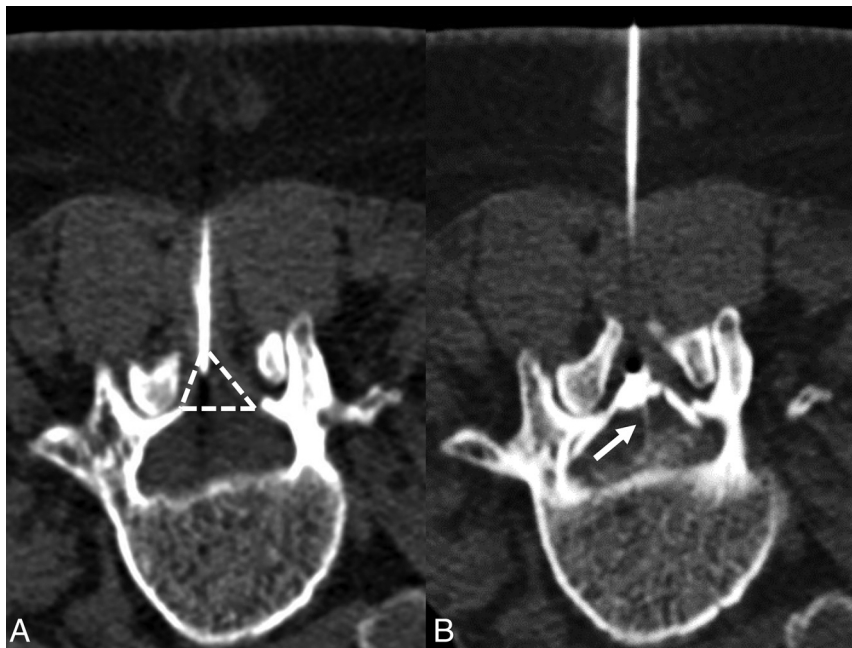


FIG 1. Procedural images from case 1. The left image (A) demonstrates the needle tip in the dorsal aspect of the dorsal epidural space (*dashed lines*). Immediately after contrast injection to the epidural space, there is a jet of contrast (B, *arrow*) that goes into the subarachnoid space, identifying the dural defect.

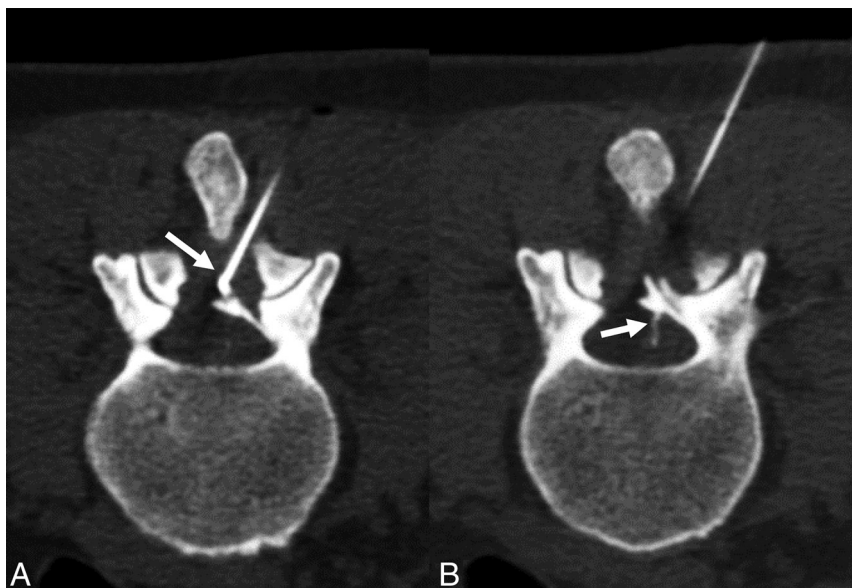

FIG 2. CT fluoroscopy images from the injection of contrast into the epidural space at L3–L4 show the needle tip in the dorsal aspect of the dorsal epidural space (A, *arrow*), and the jet of contrast (B, *arrow*) from the epidural space through a dural defect into the subarachnoid space.

Dural Defect Case 2

A 36-year-old woman underwent 2-day bilateral DSM.^{10,11} Each day included a dural puncture at L3–L4 with a 22-gauge spinal needle. The needle choice was based on provider preference. No definite evidence of a CSF-venous fistula or CSF leak was found on the DSM. Four days later, the patient underwent a multilevel blood patch as symptomatic relief for SIH (symptoms and diffuse dural enhancement on pre-DSM brain MRI) without a spinal leak identified. A 22-gauge Touhy needle was advanced into the dorsal

epidural space at L3–L4 under CT-fluoroscopic guidance, a small amount of dilute Omnipaque-300 was injected, and there was an immediate contrast jet into the subarachnoid space (Fig 2).

Additional Dural Defect Cases 3–5

Three additional patients, 25 (Fig 3A), 36 (Fig 3B), and 47 (Fig 3C) years old underwent CT-guided epidural blood patches with a contrast jet after bilateral myelography that did not find a CVF or CSF leak. The blood patches occurred 1, 2, and 2 days after myelography, respectively. As part of our clinical workflow, patients with suspected SIH but no leak site identified undergo a multilevel blood patch after myelography. We include the lumbar puncture level as part of this procedure.

DISCUSSION

PDPH is underreported and can be debilitating. Prior work has used DSM to diagnose dural defects in PDPH, but this technique requires an extra dural puncture. Our technique of injecting contrast into the dorsal epidural space is different in that it does not require another puncture to be made in the dura. We present this technique for consideration in patients with suspected PDPH.

Performing myelography, be it DSM or CT myelography, for PDPH is problematic for several reasons. First, this requires a dural puncture that carries additional risk of PDPH. Second, contrast injection for a myelogram can cause leakage into the epidural space (Fig 4) that obscures the site of a pre-existing dural defect. Contrast injection into the epidural space does not have either of these limitations.

A case report from Callen et al¹² described a similar contrast jet after epidural contrast in a postpartum patient with PDPH. Their patient had a focal dural outpouching on the lumbar spine

MRI by using a 3D T2-weighted sequence. Although our patients had MR imaging only before the lumbar puncture, this MRI finding has not been described outside of this case report. Their patient did not have an adequate response to epidural fibrin and required surgical repair. An empiric lumbar epidural blood patch is standard practice for PDPH. In equivocal cases, treatment without diagnosis becomes complicated if the patient has atypical symptoms or has incomplete response to the blood

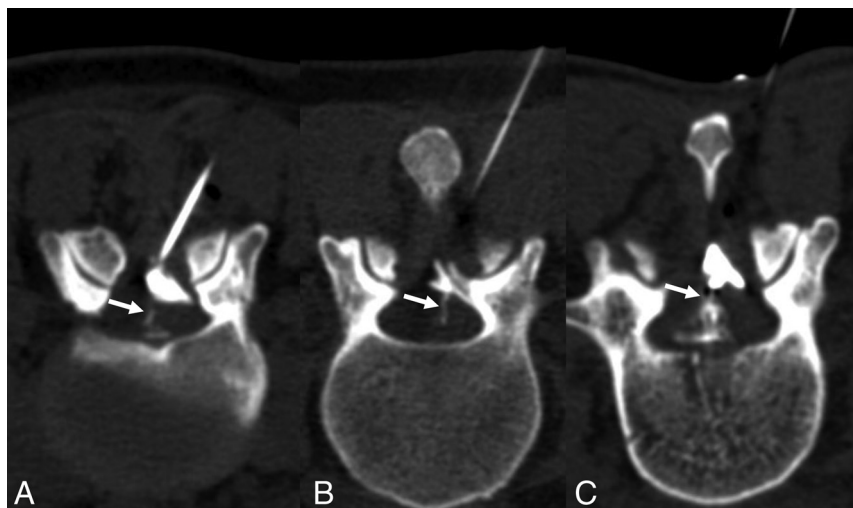


FIG 3. Three additional patients who had contrast jets (arrows) seen during CT-guided injection of contrast into the epidural space, signifying a persistent dorsal dural defect.

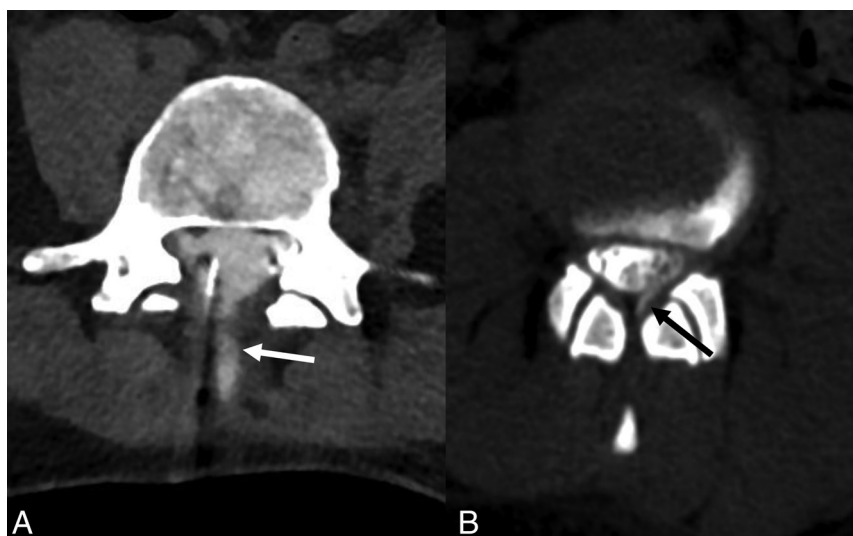


FIG 4. Two examples of extradural contrast after intrathecal injection that limit the ability of myelography to detect a dural defect. A, Image from a lateral decubitus photon-counting detector CT myelogram that shows contrast extending posteriorly along the needle tract (white arrow). B, CT imaging after DSM, after the needle was removed, shows extradural contrast at the site of prior needle placement (black arrow). Both findings would obscure the detection of contrast leakage through a dural defect present before myelography.

patch that could potentially require surgery, as highlighted by the case from Callen et al.¹²

This technical report mimics the technique that we have recently described to diagnose spinal postoperative pseudomeningoceles by injecting extrathecal contrast to detect a dural defect.¹³ That report describes injecting contrast directly into a postoperative paraspinal fluid collection for the purposes of visualizing a contrast jet into the subarachnoid space to confirm and localize the leak site. Additionally, we separately described the injection of epidural contrast to propose an alternative mechanism for intrathecal hematoma after epidural blood patch, where epidural blood traverses from the epidural space to the

subarachnoid space via a dural defect.¹⁴ If a contrast jet is seen, our practice tends to inject a smaller amount of blood, with the thought that high pressure of larger volumes could lead to more egress of blood into the subarachnoid space. The technique described in the present study is limited in that we only assess the dorsal dura, and a ventral dural defect caused by inadvertent deep needle position would not be evaluated.

Our technique, while it would remain the same for subacute versus chronic PDPH, was only demonstrated after recent lumbar puncture. This reflects our procedural practice, which performs multilevel blood patches after negative myelography work-up and does not see as many patients for chronic PDPH. Future work should be done to confirm this finding in subacute and chronic PDPH. Membrane formation has been described in the setting of spinal CSF leaks,¹⁵ and could occur at the site of dural defects in PDPH, particularly when long-standing. Our described technique could be specific but lacks sensitivity if obstructive membranes prevent the visualization of contrast jets. Even in the setting of potentially limited sensitivity, we favor epidural contrast injection rather than a new dural puncture and myelography to evaluate for persistent dural defects from a prior lumbar puncture. Our case examples had prior image-guided lumbar puncture with known puncture levels. If the prior puncture site is unknown secondary to absent records or nonimage guided technique, epidural contrast could be injected at multiple levels. Further study of this technique could also evaluate treatment outcomes related to the epidural blood patch. This CT fluoroscopy-guided procedure

does require radiation exposure, but with only minimal increased dose when compared with an isolated CT fluoroscopy-guided epidural blood patch.

PDPH is increasingly recognized as an important cause of chronic debilitating headache. When the diagnosis is not recognized promptly after the spinal procedure, or when there are atypical symptoms, additional tests are often required to establish the diagnosis. Injecting contrast into the dorsal epidural space is a technique that can help to identify dural defects that cause PDPH.

Disclosure forms provided by the authors are available with the full text and PDF of this article at www.ajnr.org.

REFERENCES

1. D'Antona L, Jaime Merchan MA, Vassiliou A, et al. **Clinical presentation, investigation findings, and treatment outcomes of spontaneous intracranial hypotension syndrome: a systematic review and meta-analysis.** *JAMA Neurol* 2021;78:329–37 [CrossRef Medline](#)
2. Williams J, Brinjikji W, Cutsforth-Gregory JK. **Natural history of spontaneous intracranial hypotension: a clinical and imaging study.** *J Neurointerv Surg* 2023;15:1124–28 [CrossRef Medline](#)
3. Häni L, Fung C, Jesse CM, et al. **Insights into the natural history of spontaneous intracranial hypotension from infusion testing.** *Neurology* 2020;95:e247–55 [CrossRef Medline](#)
4. Carroll I, Callen AL. **Beyond myths: transformative insights into spinal cerebrospinal fluid leaks and their role in persistent headache syndromes.** *Headache* 2024;64:229–32 [CrossRef Medline](#)
5. Philip JT, Flores MA, Beegle RD, et al. **Rates of epidural blood patch following lumbar puncture comparing atraumatic versus bevel-tip needles stratified for body mass index.** *AJNR Am J Neuroradiol* 2022;43:315–18 [CrossRef Medline](#)
6. Barad M, Carroll I, Reina MA, et al. **Did she have an epidural? The long-term consequences of postdural puncture headache and the role of unintended dural puncture.** *Headache* 2021;61:1314–23 [CrossRef Medline](#)
7. Gauthama P, Kelkar A, Basar SMA, et al. **Incidence of persistent headache at 18 months following accidental dural puncture in the obstetric population: a prospective service evaluation in 45 patients.** *Headache* 2019;59:97–103 [CrossRef Medline](#)
8. Niraj G, Critchley P. **Management and outcomes of persistent headache after accidental dural puncture in the obstetric population: a 9-year prospective audit.** *Headache* 2023;63:71–78 [CrossRef Medline](#)
9. Schievink WI, Maya MM, Moser FG. **Digital subtraction myelography in the investigation of post-dural puncture headache in 27 patients: technical note.** *SPI* 2017;26:760–64 [CrossRef](#)
10. Kim DK, Brinjikji W, Morris PP, et al. **Lateral decubitus digital subtraction myelography: tips, tricks, and pitfalls.** *AJNR Am J Neuroradiol* 2020;41:21–28 [CrossRef Medline](#)
11. Shlapak DP, Mark IT, Kim DK, et al. **Incremental diagnostic yield and clinical outcomes of lateral decubitus CT myelogram immediately following negative lateral decubitus digital subtraction myelogram.** *Neuroradiol J* 2023;36:593–600 [CrossRef Medline](#)
12. Callen AL, Lennarson P, Carroll IR. **A causative role for remote dural puncture and resultant arachnoid bleb in new daily persistent headache: a case report.** *Headache* 2023;63:981–83 [CrossRef Medline](#)
13. Mark IT, Madhavan AA, Delone DR, et al. **Direct pseudomeningocele contrast injection for spinal CSF leak localization.** *Neuroradiol J* 2023 Dec 26. Epub ahead of print. [CrossRef Medline](#)
14. Mark I, Madhavan A, Carr C, et al. **Intrathecal hematoma following epidural blood patch: an alternative mechanism to intrathecal puncture.** *Neuroradiol J* 2024 Mar 23. Epub ahead of print. [CrossRef Medline](#)
15. Häni L, Fung C, El Rahal A, et al. **Distinct pattern of membrane formation with spinal cerebrospinal fluid leaks in spontaneous intracranial hypotension.** *Oper Neurosurg (Hagerstown)* 2024;26:71–77 [CrossRef Medline](#)