

Generic Contrast Agents

Our portfolio is growing to serve you better. Now you have a *choice*.



FRESENIUS
KABI

[VIEW CATALOG](#)

AJNR

Neonatal Periventricular Leukomalacia: Real-Time Sonographic Diagnosis with CT Correlation

Peter P. Chow, J. Gerard Horgan and Kenneth J. W. Taylor

AJNR Am J Neuroradiol 1985, 6 (3) 383-388

<http://www.ajnr.org/content/6/3/383>

This information is current as
of May 13, 2025.

Neonatal Periventricular Leukomalacia: Real-Time Sonographic Diagnosis with CT Correlation

Peter P. Chow^{1,2}
J. Gerard Horgan^{1,3}
Kenneth J. W. Taylor¹

The utility of real-time sonography in the diagnosis of neonatal periventricular leukomalacia (PVL) has been described only recently. Six cases are reported of PVL diagnosed by serial real-time scanning. The sonographic findings were correlated with the computed tomographic findings and the clinical history. In five of six infants in whom scanning was performed, characteristic multiseptated periventricular cavitations developed 2–3 weeks after birth or later. A transition from normal to increased periventricular echogenicity was often observed before the development of the periventricular cavitations in nonhemorrhagic PVL. The parenchymal abnormality demonstrated by sonography correlated well with an abnormal neurologic outcome. It is suggested that serial real-time scanning be performed in neonates whose history suggests the possibility of hypoxic-ischemic brain injury. Nonspecific predictors of PVL include seizures, apnea, disturbed mental status, abnormal muscle tone, and leg weakness.

Periventricular leukomalacia (PVL) results from an ischemic insult to the neonatal brain with involvement of the periventricular white matter adjacent to the external angles of the lateral ventricles [1–5]. It is commonly found at autopsy in the brains of neonates. However, it is rarely diagnosed in living infants. Although real-time sonography has been used widely to diagnose intracranial hemorrhage and other abnormalities of the brains in neonates, the sonographic features of PVL are not well known [6–9]. We report six cases of neonatal PVL diagnosed primarily by real-time sonography. The early sonographic findings and the evolution of PVL on serial sonograms are emphasized. Computed tomographic (CT) scans were obtained to confirm the nature and extent of the parenchymal lesions.

Subjects and Methods

Cranial sonograms were obtained with a real-time sector scanner (ATL 300). A 5 MHz transducer with a 90° field of view was used. Multiple coronal and parasagittal images were obtained through the anterior fontanelle. At least four examinations were performed in all but one of our patients (case 6). The indication for serial sonography was usually an abnormal neurologic examination or persistent seizure activity.

Cranial CT scans were obtained on a GE 8800 or 9800 scanner. The patients were scanned at 5 mm intervals with 5-mm-thick slices.

A summary of patients and clinical data is shown in table 1. The sonographic and CT findings are shown in table 2. Representative cases are illustrated.

Representative Case Reports

Case 1

A twin girl was born at 28 weeks gestation with a birth weight of 1025 g. The pregnancy was complicated by premature rupture of membranes (PROM) 6 weeks before delivery. A cesarean section was performed. The Apgar scores were 6 at both 1 and 5 min. The infant received assisted ventilation for 3½ weeks because of hyaline membrane disease and

This article appears in the May/June 1985 issue of *AJNR* and the July 1985 issue of *AJR*.

Received April 2, 1984; accepted after revision August 28, 1984.

¹ Department of Diagnostic Radiology, Yale University School of Medicine, 333 Cedar St., New Haven, CT 06510. Address reprint requests to K. J. W. Taylor.

² Present address: Department of Radiology, School of Medicine, Health Science Center, State University of New York at Stony Brook, Stony Brook, NY 11784.

³ Present address: Department of Radiology, Meath Hospital, Dublin, Ireland.

AJNR 6:383–388, May/June 1985

0195–6108/85/0603–0383

© American Roentgen Ray Society

TABLE 1: Summary of Clinical Findings in Infants with Periventricular Leukomalacia

Case No. (gestation [weeks], birthweight [grams])	Maternal History	Apgar Scores at 1, 5 min	Cardiac Status	Respiratory Status	CSF Examination	Neurologic Findings	
						Neonatal Period	Postneonatal Period
1 (28, 1025)	PROM, CS	6, 6	Pericardial effusion	RDS, apnea	Normal	Seizure	Lost to F/U
2 (28, 1200)	None	8, 3	PDA, CHF	BPD	↑ Pressure	Seizure	Spastic diplegia at 6 mo; delayed devel- opment at 13 mo
3 (32, 1290)	PROM	7, —	Bradycardia	BPD, apnea	Normal	Seizure, hypertonia	Scissoring of legs at 2 mo
4 (32, 1580)	Breech, head dystocia	3, 5	PDA	RDS, apnea	Hemorrhagic	Seizure, hyperreflexia, hypertonia in legs	Lost to F/U
5 (28, 1000)	AP, CS	1, 4	PDA	BPD	Not performed	Hyperreflexia, hypertonia in legs	Spastic diplegia at 8 mo
6 (38, 3500)	AP, CS	2, 3	Hypotension	None	Normal	Seizure, hyperreflexia, hypertonia in legs	Lost to F/U

Note.—CSF = cerebrospinal fluid; PROM = premature rupture of membrane; CS = cesarean section; RDS = respiratory distress syndrome; F/U = follow-up; PDA = patent ductus arteriosus; CHF = congestive heart failure; BPD = bronchopulmonary dysplasia; mo = months; AP = abruption of placenta.

TABLE 2: Sonographic and CT Findings in Infants with Periventricular Leukomalacia

Case No. (Total No. of Sonograms)	Early Sonography (<2 weeks)		Late Sonography (≥2 weeks) (time of cavitations)	Ventricu- lomegaly	CT Findings
	SEH/IVH	Periventricular Echogenicity			
1 (10)	N→I (11d)	20d	—	Periventricular and subcortical lu- cency
2 (14)	N	40d	+	Periventricular and subcortical lu- cency
3 (4)	Grade I	N→I (8d)	13d	+	Periventricular and subcortical lu- cency
4 (14)	Grade II	I (2d)	17d	+	Periventricular hemorrhage
5 (8)	N→I (9d)	38d	—	Periventricular lucency
6 (1)	I (8d)	Not performed	—	Periventricular lucency

Note.—SEH = subependymal hemorrhage; IVH = intraventricular hemorrhage; N = normal; I = increased; d = days.

occasional apneic episodes. Myoclonic seizures were noted soon after birth. Several spinal taps showed no evidence of infection. A cranial sonogram on the second day of life was normal (figs. 1A and 1B). A sonogram on the 11th day of life showed increased echogenicity of the periventricular areas (figs. 1C and 1D). Multiseptated cavitations had developed within the periventricular echogenic areas by 3 weeks of age (figs. 1E and 1F). A cranial CT scan on the same day demonstrated prominent bilateral irregular hypodense lesions in the periventricular white matter extending toward the cortex, consistent with PVL (fig. 1G).

Case 2

A 1200 g boy was born at 28 weeks gestation by spontaneous vaginal delivery. Apgar scores were 8 and 3 at 1 and 5 min, respec-

tively. The infant's hospital course was complicated by respiratory distress syndrome, pneumothoraces, and bronchopulmonary dysplasia. A patent ductus arteriosus (PDA) resulted in congestive heart failure and was treated initially with indomethacin and subsequently by surgical ligation at 3 weeks of age.

Several cranial sonograms were normal in the first month of life. A sonogram 6 weeks after birth, however, revealed ventriculomegaly and bilateral, markedly increased echogenicity of the periventricular region with multiseptated cavitations (figs. 2A and 2B). CT on the same day demonstrated periventricular and subcortical lucencies and widening of the interhemispheric fissure, consistent with PVL (fig. 2C).

A ventriculoperitoneal shunt was placed because of progressive hydrocephalus. Spastic diplegia was evident at the 6 month neurologic follow-up. At 13 months of age, the patient had delayed developmental age equivalent to 5¼ months.

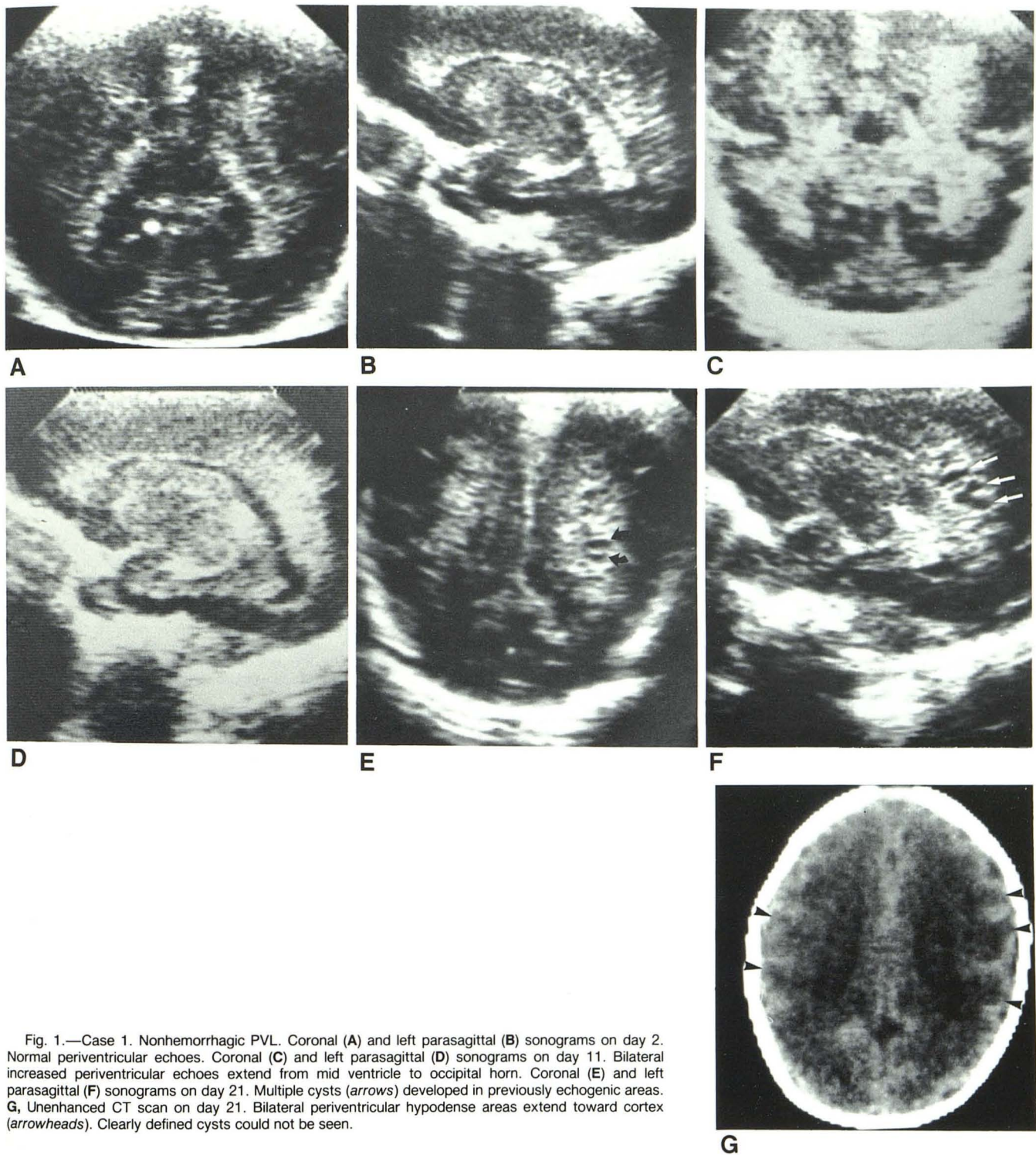


Fig. 1.—Case 1. Nonhemorrhagic PVL. Coronal (A) and left parasagittal (B) sonograms on day 2. Normal periventricular echoes. Coronal (C) and left parasagittal (D) sonograms on day 11. Bilateral increased periventricular echoes extend from mid ventricle to occipital horn. Coronal (E) and left parasagittal (F) sonograms on day 21. Multiple cysts (arrows) developed in previously echogenic areas. G, Unenhanced CT scan on day 21. Bilateral periventricular hypodense areas extend toward cortex (arrowheads). Clearly defined cysts could not be seen.

Case 3

A 1290 g boy was born at 31–32 weeks gestation by vaginal delivery. PROM occurred at 32 hr before delivery. The Apgar score was 7 at 1 min. The infant had respiratory distress syndrome followed by bronchopulmonary dysplasia. Occasional episodes of apnea and bradycardia were noted during the hospitalization. The infant was

noted to have alternating states of alertness and occasional seizure-like activity with scissoring of his legs and increased muscle tone. Two electroencephalograms were normal. Cerebrospinal fluid culture was negative.

A sonogram at 2 days of age showed a left germinal matrix hemorrhage. A sonogram 8 days after birth revealed ventriculomegaly and increased periventricular echogenicity. Cranial CT at this time

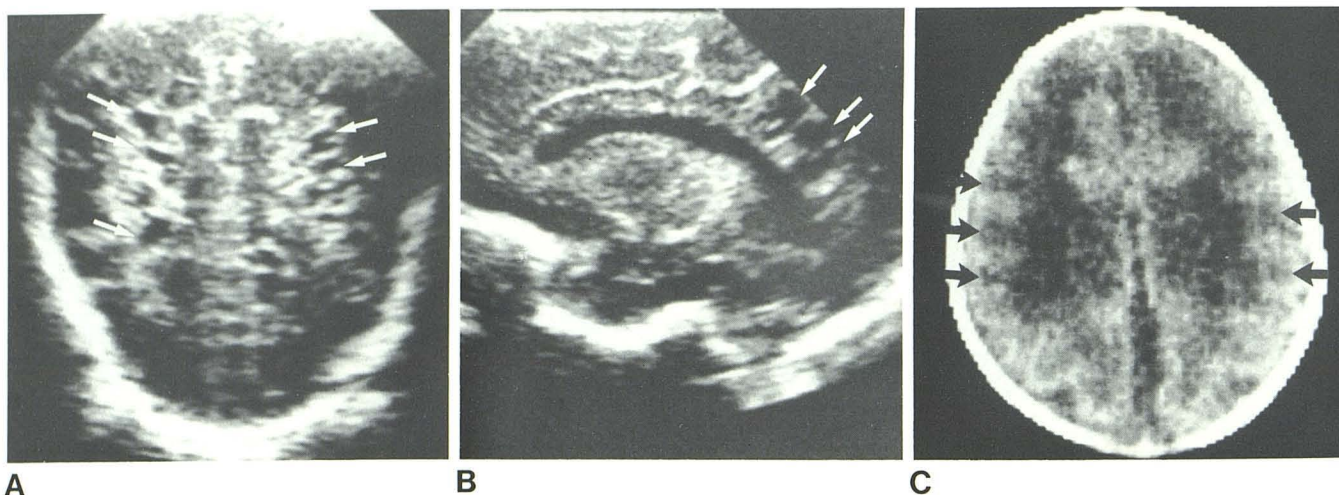


Fig. 2.—Case 2. Nonhemorrhagic PVL. Coronal (A) and right parasagittal (B) sonograms at 40 days of age. Multiple bilateral periventricular cysts in region of trigone of lateral ventricle (arrows). Mild ventriculomegaly. C, Un-

enhanced CT scan at 40 days of age. Marked bilateral periventricular hypodense areas with subcortical extension (arrows). Widening of interhemispheric fissure indicated cerebral atrophy.

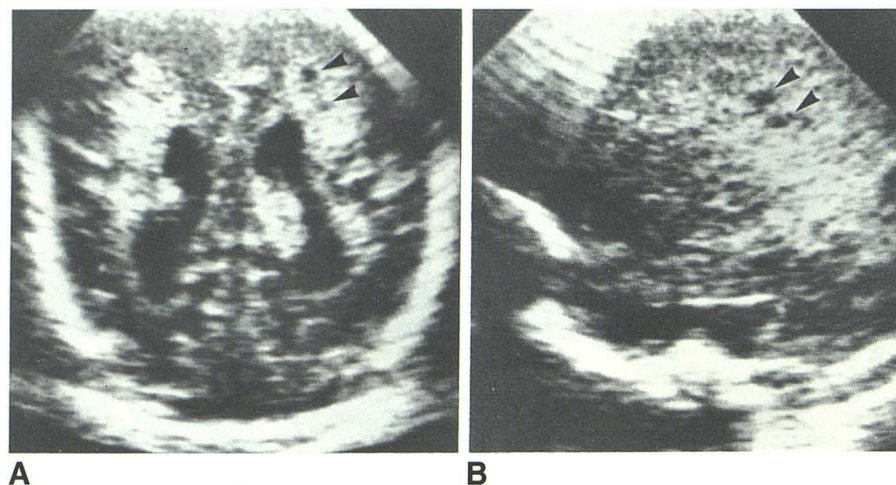


Fig. 3.—Case 3. Nonhemorrhagic PVL. Initial sonograms showed left germinal matrix hemorrhage at 2 days and ventriculomegaly and increased periventricular echogenicity at 8 days. Coronal (A) and left parasagittal (B) sonograms on day 13. Small cysts (arrowheads) had developed within periventricular echogenic areas. Lateral borders of echogenic areas were irregular but well defined.

revealed marked periventricular hypodense areas. A sonogram at 13 days of age showed early cavitations within the echogenic periventricular areas (figs. 3A and 3B).

Case 4

A 1580 g boy was born at about 32 weeks gestation by breech vaginal delivery. The infant had asphyxia at birth with Apgar scores of 3 and 5 at 1 and 5 min, respectively. Due to hyaline membrane disease and episodes of apnea, assisted ventilation was required for 5 weeks. A PDA was treated with indomethacin. Myoclonic seizure was noted 2 days after birth. Neurologic examination revealed symmetric, brisk deep tendon reflexes, decreased active tone, and increased passive tone in the legs.

A sonogram on the second day of life revealed bilateral subependymal and intraventricular hemorrhage (figs. 4A–4C). There were also bilateral intense periventricular echoes that corresponded to periventricular hemorrhage on CT (fig. 4D). Multiseptated cavitations were shown by sonography to have developed within the periventricular echogenic areas on the 17th day (fig. 4E). Subsequent sonograms

showed confluence of the small cysts and communication of these cysts with the ventricles (figs. 4F and 4G). CT showed periventricular and subcortical lucencies but did not reveal definite cysts.

Discussion

PVL is a common variety of neonatal hypoxic-ischemic encephalopathy [10]. The reported incidence of PVL varies with the selection of case material. The overall autopsy incidence of PVL approximates 20% [1–6]. PVL is observed particularly often in premature infants with postnatal survival of more than 6 days [4]. A significant history of cardiorespiratory disturbances in the neonatal period is especially common among these patients.

There are no early neurologic findings specific for PVL. Seizure, apneic spells, disturbance in mental status, abnormal muscle tone, and leg weakness may be found [10]. PVL is not a lethal lesion, but may lead to degeneration of the corticospinal tract, particularly to the legs. The major long-

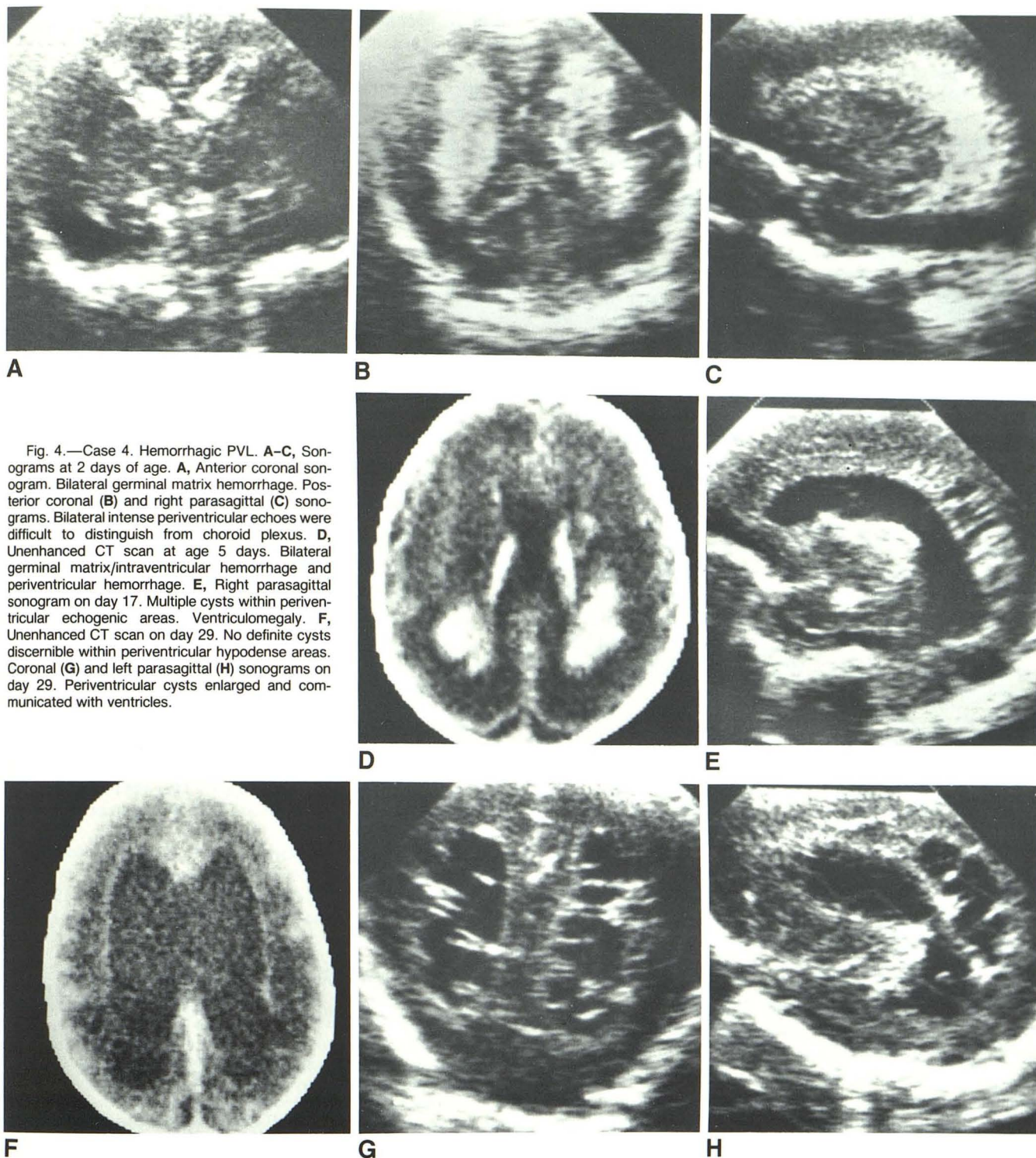


Fig. 4.—Case 4. Hemorrhagic PVL. A–C, Sonograms at 2 days of age. A, Anterior coronal sonogram. Bilateral germinal matrix hemorrhage. Posterior coronal (B) and right parasagittal (C) sonograms. Bilateral intense periventricular echoes were difficult to distinguish from choroid plexus. D, Unenhanced CT scan at age 5 days. Bilateral germinal matrix/intraventricular hemorrhage and periventricular hemorrhage. E, Right parasagittal sonogram on day 17. Multiple cysts within periventricular echogenic areas. Ventriculomegaly. F, Unenhanced CT scan on day 29. No definite cysts discernible within periventricular hypodense areas. Coronal (G) and left parasagittal (H) sonograms on day 29. Periventricular cysts enlarged and communicated with ventricles.

term sequela of PVL is spastic diplegia. Severe lesions may affect the arms as well as visual and intellectual functions.

Most authors now believe PVL to be the result of a localized infarctive process in watershed areas between the ventriculopetal and ventriculofugal branches of deep penetrating arteries [2–4]. The two most common sites for PVL are the occipital radiation at the trigone of the lateral ventricles and

the white matter around the foramen of Monro. PVL has not been attributed to generalized hypoxia because these lesions are pathologically characteristic of infarction and because areas characteristically damaged by hypoxia (cerebellar cortex and hippocampus) are normal [2, 3].

The evolution of PVL was postulated by DeReuck et al. [2] in an autopsy series of 13 cases. The earliest stage is char-

acterized by foci of coagulation necrosis. Later, there is proliferation of astrocytes and macrophages, followed by phagocytosis of the necrotic tissue, with resulting periventricular cavities of varying size surrounded by gliosis. If the ependyma is destroyed, the cavities may then communicate with the ventricular system. Secondary hemorrhage, ranging from microscopic to massive, may occur within these periventricular infarcts, and this feature was demonstrated in 25% of cases studied at postmortem examination by Armstrong and Norman [3]. Thinning of the white matter can lead to ventriculomegaly in larger infarcts.

The progression of the sonographic findings of PVL in our study correlates well with the pathologic evolution. The initial sonogram shortly after birth is often normal. Increased periventricular echogenicity may be demonstrated in the first 2 weeks of life, representing ischemia or hemorrhage [8, 11]. CT at this stage demonstrates periventricular lucency unless secondary hemorrhage has occurred. It is not until about 2–3 weeks after birth and sometimes later that the characteristic periventricular multiseptated cysts develop and then the diagnosis of PVL becomes certain. Therefore, in neonates with a history of asphyxia and a normal sonogram shortly after birth, follow-up sonograms should be obtained, perhaps on a weekly basis.

Our study demonstrated the value of sonography in the diagnosis of neonatal PVL. The location and extent of the parenchymal lesions can be assessed accurately by sonography. Although it is unable to distinguish hemorrhagic from nonhemorrhagic infarction, sonography demonstrates periventricular cystic changes not well seen on CT. The fact that neither CT nor sonography detects PVL as often as in autopsy series suggests that both have limited sensitivity. Magnetic resonance imaging may prove to be superior [12, 13].

Subependymal/intraventricular hemorrhage, a more common hemorrhagic lesion of premature infants, may extend into the periventricular white matter and mimic hemorrhagic PVL. The characteristic position for PVL, dorsal and lateral to the germinal matrix layer, helps differentiate these entities.

Similarly, focal and multifocal ischemic brain necrosis is associated with cavity formation, tending to follow the distribution of the major cerebral vessels. Multiple cystic encephalomalacia results from a variety of insults [14, 15], producing cysts of relatively large size and not necessarily located in the periventricular white matter.

Recognition of PVL is of considerable clinical significance as it implies significant brain damage and a less favorable neurologic developmental outcome. Prompt diagnosis with real-time sonography may affect family counseling and further management. Vigorous supportive care, particularly maintenance of ventilation and perfusion, and control of seizure can be instituted to prevent accentuation of the existing injury

[10]. In neonates at risk for the development of PVL, the periventricular echogenicity should be evaluated carefully. Appreciation of the abnormal, increased echogenicity equal to or greater than that of the choroid plexus and in the characteristic anatomic location should raise suspicion of PVL. The predictable evolution of the sonographic appearances on sequential scans will establish the diagnosis of this distinct entity.

REFERENCES

1. Banker BQ, Larroche JC. Periventricular leukomalacia of infancy. *Arch Neurol* **1962**;7:386–410
2. DeReuck J, Chattha AS, Richardson EP. Pathogenesis and evolution of periventricular leukomalacia in infancy. *Arch Neurol* **1972**;27:229–236
3. Armstrong D, Norman MG. Periventricular leukomalacia in neonates: complications and sequelae. *Arch Dis Child* **1974**;49:367–375
4. Shuman RM, Selednik LJ. Periventricular leukomalacia. *Arch Neurol* **1980**;37:231–235
5. Leech RW, Alvord EC. Morphologic variations in periventricular leukomalacia. *Am J Pathol* **1974**;74:591–600
6. Hill A, Melson GL, Clark HB, Volpe JJ. Hemorrhagic periventricular leukomalacia: diagnosis by real-time ultrasound and correlation with autopsy finding. *Pediatrics* **1982**;69:282–284
7. Levene MI, Wigglesworth JS, Dubowitz V. Hemorrhagic periventricular leukomalacia in the neonate: a real-time ultrasound study. *Pediatrics* **1983**;71:794–797
8. Martin DJ, Hill A, Fitz CR, Daneman A, Havill DA, Becker LE. Hypoxic/ischaemic cerebral injury in the neonatal brain: a report of sonographic features with computed tomographic correlation. *Pediatr Radiol* **1983**;13:307–312
9. Manger MN, Feldman RC, Brown WJ, Mitchell LS, Wattarn KF, Shields WD. Intracranial ultrasound diagnosis of neonatal periventricular leukomalacia. *J Ultrasound Med* **1984**;3:59–63
10. Volpe JJ. *Neurology of the newborn*. Philadelphia: Saunders, **1981**:216–218
11. Hill A, Martin DJ, Daneman A, Fitz CR. Focal ischemic cerebral injury in the newborn: diagnosis by ultrasound and correlation with computed tomographic scan. *Pediatrics* **1983**;71:790–793
12. Johnson MA, Pennock JM, Bydder GM, et al. Clinical NMR imaging of the brain in children: normal and neurologic disease. *AJNR* **1983**;4:1013–1026, *AJR* **1983**;141:1005–1018
13. Levene MI, Whitelaw KA, Dubowitz V, et al. Nuclear magnetic resonance imaging of the brain in children. *Br Med J [Clin Res]* **1982**;285:774–776
14. Chutorian AM, Michener RC, Defendini R, Hilal SK, Gamboa ET. Neonatal polycystic encephalomalacia: four new cases and review of the literature. *J Neurol Neurosurg Psychiatry* **1979**;42:154–160
15. Stannard MW, Jimenez JF. Sonographic recognition of multiple cystic encephalomalacia. *AJNR* **1983**;4:1111–1114, *AJR* **1983**;141:1321–1324