

Generic Contrast Agents

Our portfolio is growing to serve you better. Now you have a *choice*.



FRESENIUS
KABI

[VIEW CATALOG](#)

AJNR

Incidental paranasal sinus abnormalities on CT of children: clinical correlation.

C M Glasier, D P Ascher and K D Williams

AJNR Am J Neuroradiol 1986, 7 (5) 861-864

<http://www.ajnr.org/content/7/5/861>

This information is current as
of May 16, 2025.

Incidental Paranasal Sinus Abnormalities on CT of Children: Clinical Correlation

Charles M. Glasier¹
David P. Ascher²
Kenneth D. Williams³

The paranasal sinuses were prospectively evaluated by CT, clinical history, and physical examination in infants and children having cranial CT for indications unrelated to upper respiratory inflammation (URI). One hundred and one CT scans were studied, and sinus abnormalities were detected in 18% of patients older than 1 year and without signs or symptoms of URI. When signs and/or symptoms of recent URI were present, the incidence of abnormalities was 31%. Maxillary antra were not identifiable or were opacified in 72% of all infants under 1 year old. Because of the high incidence of sinus abnormalities on CT in children with and without evidence of recent URI, abnormalities should not be ascribed to sinusitis without close clinical correlation.

Sinus radiographs are frequently obtained for evaluation of suspected sinusitis in infants and children. The significance of sinus radiograph abnormalities in young patients is controversial because of the reported frequency of abnormalities in asymptomatic populations. Indeed, Shopfner and Rossi [1] identified radiographic abnormalities in 40 of 46, or 87%, of patients under age 2, only seven of whom had clinical symptoms suggestive of sinusitis. Interpretation of sinus radiographs in young children is frequently compromised by motion, positioning, small size of the paranasal sinuses, and overlying soft-tissue disease. Cranial CT is commonly performed in children for indications other than sinusitis and is the definitive imaging technique for sinus disease. We report the prospective correlation of clinical findings with CT sinus abnormalities in an unselected group of infants and children having cranial CT for reasons other than suspected sinus disease.

Subjects and Methods

Between October 1984 and June 1985, cranial CT scans in pediatric patients were evaluated prospectively for paranasal sinus abnormalities and correlated with history and physical examination. Scans that did not adequately show the sinuses were excluded. Patients were excluded if clinical interviews and physical examinations could not be performed within 24 hr before or 48 hr after the CT examination, or if the CT was performed for evaluation of suspected sinus disease. A total of 101 scans in 99 patients met criteria for inclusion in the study. The patient population consisted of 54 boys and 45 girls, ranging in age from 1 day to 16 years. Indications for CT included seizures, abnormal neurologic examinations, ventricular shunt evaluation, cerebral trauma, developmental delay, CNS neoplasia, headache, and congenital anomalies of the CNS and skull.

All scans were obtained with a GE 8800 scanner, using a 9.6-sec scan time. Children aged 3 years and under were sedated and studied with a protocol of contiguous axial slices parallel to the canthomeatal line with 5 mm collimation and incrementation. Scans of children 4 years and older were accomplished with 10 mm collimation and incrementation. Although images were routinely evaluated at soft-tissue windows, infants and cases of suspected volume-averaging abnormalities were also studied at bone window settings. The scans were reviewed by two radiologists, and a consensus diagnosis was reached. Physical examination and historic data were not known at the time of scan review.

Clinical interview of the patient and/or parents and physical examination of the upper

Received October 7, 1985; accepted after revision February 4, 1986.

¹ Department of Radiology, University of Arkansas for Medical Sciences, Arkansas Children's Hospital, 804 Wolfe St., Little Rock, AR 72202-3591. Address reprint requests to C. M. Glasier.

² PSC 3 Box 15907, APO San Francisco, CA 96432-0006.

³ Department of Radiology, Wilford Hall USAF Medical Center, SGHQRD, Lackland AFB, TX 78236-5300.

AJNR 7:861-864, September/October 1986

0195-6108/86/0705-0861

© American Society of Neuroradiology

respiratory tract were performed by a pediatrician. Historic information solicited in each case included presence of headache, rhinorrhea, cough, sore throat, fever, otitis, halitosis, dental pain, and facial pain or swelling. Previous episodes of sinusitis as well as a history of asthma or other atopic disorders were recorded. A positive history for recent URI consisted of rhinorrhea or cough within the 2 weeks preceding the CT examination. Physical examination of the nose, throat, and chest were considered positive for URI if a clear nasal discharge with nasal mucosal erythema and injection of the pharynx and/or conjunctiva were present or if an exudative pharyngitis was present.

Results

Patients were divided into three groups on the basis of age: under 1 year, 1 to 6 years, and 7 to 16 years. There were 18, 50, and 33 patients in each group, respectively. Patients were also placed in one of two categories on the basis of their clinical history and physical examination. Those with no history of recent URI and a normal physical examination were considered to be URI negative. A patient with a positive history and/or physical was placed into the URI positive group. A total of 70 patients (69%) were URI negative while 31 (31%) were URI positive. The percentage of URI positive for each age group was 28, 40, and 18, respectively.

Sinuses were considered normal if no soft-tissue density was present within a clearly marginated, aerated cavity (Fig. 1) [2]. Any appearance other than this was considered abnormal. The presence of one or more abnormal sinuses on CT placed the patient in the abnormal-appearing-sinus group. Sinus appearance versus URI group and age is given in Table 1.

Total opacification was present if a sinus was completely filled with soft-tissue density yet a distinct bony margin was identifiable (Fig. 2). Any soft-tissue density along a sinus wall that was not clearly polypoid in configuration was classified as mucosal thickening with further categorization into thickening less than or greater than 4 mm (Fig. 3). When no bony margin or sinus aeration could be identified, the sinus was considered underdeveloped. Polypoid soft-tissue masses (Fig. 4) and air-fluid levels were occasionally seen. Due to difficulty in measuring mucosal thickening in the ethmoid sinuses, only categories of total and subtotal opacification were described. Thickening and sclerosis of antral walls, sometimes seen in older children with chronic sinus disease, were not found in our patients.

Of 202 maxillary antra, 79% were normal in URI negative patients and 60% were normal in the URI positive group. Although total opacification was found almost equally in both populations, mucosal thickening greater than 4 mm occurred four times as often in the URI positive group. Underdevelopment was seen bilaterally in one 6-year-old with Treacher Collins syndrome. The other five patients with this finding were under 15 months old. The three maxillary antra with polypoid soft-tissue masses and a single antrum with an air-fluid level were all detected in URI negative patients. Ethmoid sinus abnormalities occurred less frequently, with 99% normal sinuses in the URI negative group, and 92% normal sinuses in the URI positive group. Isolated ethmoid changes were not

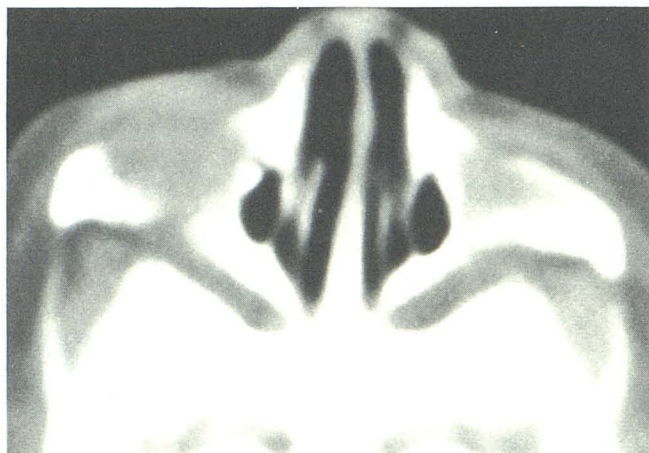


Fig. 1.—Normal maxillary sinus CT in a 3-week-old boy scanned because of facial hemangioma (not shown).

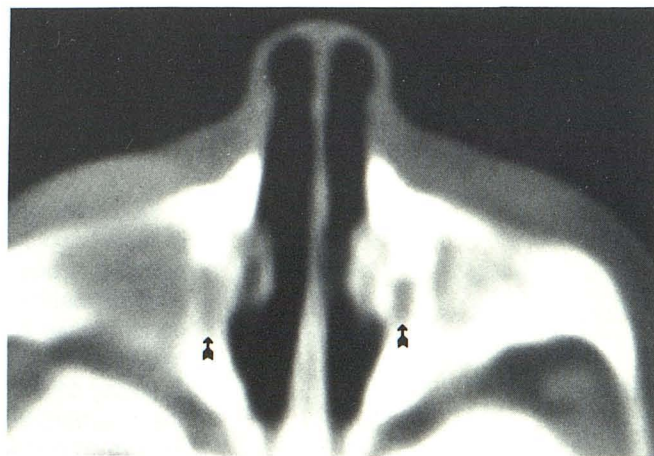


Fig. 2.—Totally opacified rudimentary maxillary sinus cavities (arrows) in a 1-day-old boy scanned after traumatic delivery.

TABLE 1: Sinus Appearance vs URI* Group and Age

Age (years)	URI—		URI+		Totals
	Normal	Abnormal	Normal	Abnormal	
Less than 1	5	8	0	5	18
1–6	25	5	13	7	50
6 and older	22	5	5	1	33
Totals	52	18	18	13	101

* URI = upper respiratory inflammation.

encountered, as all these patients had bilateral maxillary abnormalities consisting of either total opacification or mucosal thickening greater than 4 mm. The single frontal sinus abnormality was a mucocele incidentally discovered in a 15-year-old. Sphenoid sinus abnormalities were not present in any of the patients.

Statistical analysis of the data was performed using Fisher's

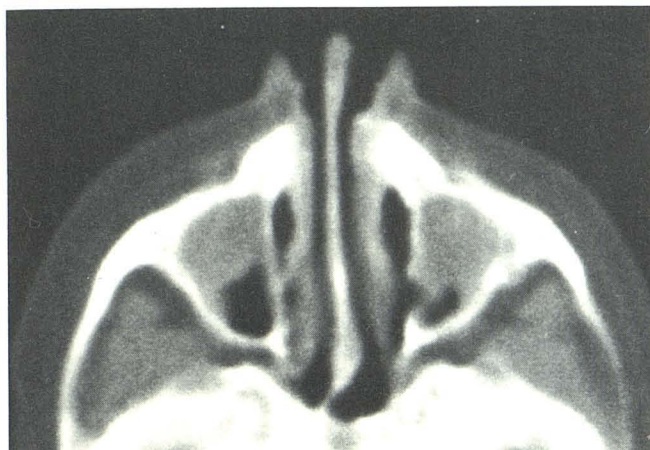

Fig. 3.—Mucosal thickening and/or loculated fluid in the maxillary sinuses of a 4-year-old girl with negative history and physical examination for upper respiratory inflammation.

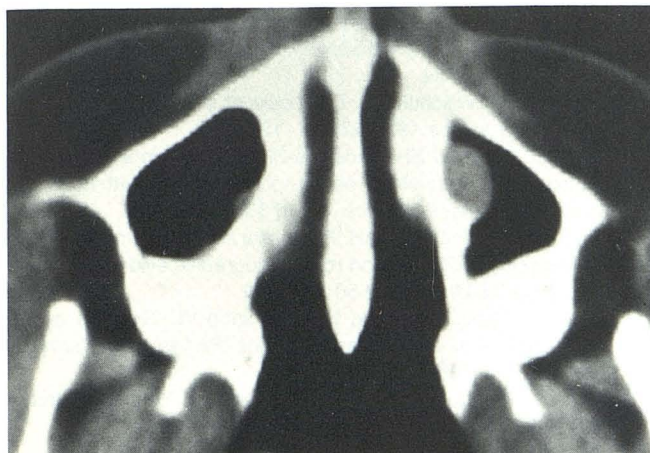

Fig. 4.—Bilateral polypoid soft-tissue densities in a clinically normal 14-year-old girl.

exact test. When the prevalence rates of patients with abnormal sinuses in the URI negative and URI positive populations were compared, no statistically significant differences were found ($p < 0.05$). With the exception of the 6 and older age group, however, a higher prevalence rate of abnormalities was seen in the URI positive patients. In the under 1 year age group, the abnormal rates were 62% in URI negative and 100% in URI positive groups, with rates of 17% and 35% for the respective groups in the 1-to-6 age range. Comparisons based on differences in age did demonstrate statistically significant differences in the prevalence rates of patients with abnormal sinuses. Patients under 1 year old had significantly greater rates than those over 1 year in both the URI negative and URI positive groups as well as for the entire patient population. When the prevalence rate of abnormal sinuses for all patients less than 1 (72%) is compared with the rate for all patients older than 1 (22%), the difference is significant ($p < 0.0001$).

Discussion

The significance of radiographic sinus abnormalities in infants and children remains a controversial and confusing topic. The need for clarification has recently been emphasized [3]. Previous investigators have attempted to correlate plain film radiographic sinus abnormalities with clinical respiratory symptoms and even antral puncture. Wald et al. [4] asserted that radiographic findings of total opacification, air-fluid levels, or mucous membrane thickening in conjunction with symptoms referable to the upper respiratory tract predicted the presence of bacteria in maxillary sinus aspirates in 75% of children. Only two children under age 2 were included in that study because of technical difficulty with sinus aspirates in young children. It is in this age group that sinus radiograph interpretation is most difficult.

Kogutt and Swischuk [5] found that 96% of children clinically suspected of sinusitis have abnormal sinus radiographs and stated that "although sinusitis could often be suspected clinically, its unequivocal documentation could be accomplished only with roentgenograms." More recently, Kovatch et al. [6] suggested that abnormal sinus radiographs in children over 1 year old are infrequent and are generally associated with upper respiratory tract inflammation. However, sinus radiographs in their patients under 1 year old were frequently abnormal irrespective of respiratory signs and symptoms.

Maresh and Washburn [7] found abnormal sinus radiographs in 58% of routine sinus radiographs in normal children under 1 year old. The percentage of abnormal radiographs dropped to approximately 35% in the preschool years and to 15% in children age 12 or older. They did not categorize radiographic sinus abnormalities, however, and designated as pathologic any sinus cavity without "clear, sharp borders" or that was not "entirely translucent."

Our study was designed prospectively to correlate sinus CT findings with carefully performed concurrent history and physical examination of the upper respiratory tract. We found that 31 of 101, or 31%, of the children in our study group had symptoms or physical findings of recent URI, which agrees with the known high incidence of URI in children. In our patients over 1 year old without signs or symptoms of respiratory inflammation, 10 of 57, or 18%, had abnormal CT findings, none of which were specific to this group. This agrees with the 10% figure noted by Kovatch et al. [6] in children over 1 year old. The causes of abnormal CT findings in patients without clinical signs of URI or sinusitis are unclear but could be due to subclinical sinus inflammatory disease or failure of adequate drainage of the maxillary sinus, which has a nondependent ostium. Very large retention cysts or polyps unrelated to sinus inflammation could also cause soft-tissue filling of the antra. An allergic origin could explain mucosal thickening or polyps, and four of nine patients with positive allergic histories in our population had abnormal CT. Neither patient with apparent maxillary polyps had an allergic history.

In the children over 1 year with signs or symptoms of recent URI, 8 of 26, or 31%, had abnormal CT. Three patients had mucopurulent nasal discharge suggestive of sinusitis, and two had abnormal CT. CT findings in these patients were not

specific, but this group is very small. The presence of URI did seem to correlate with the degree of mucosal thickening, in that six of eight patients older than 1 year with URI and abnormal CT had mucosal thickening greater than 4 mm.

In infants under 1 year, 13 of 18, or 72%, had abnormal scans. Thirteen antra were totally opacified, four were subtotally opacified, and in five instances, an antral cavity could not be detected. In contrast, only three antra were undetectable in children over 1 year, two being in the patient with Treacher Collins syndrome. Since maxillary and ethmoid sinus cavities are usually present by the second trimester of fetal life [8], it is possible that sinus cavities could have been detected in all infants using 1.5-mm collimation, but that technique was not indicated in our patients. When CT is performed for the specific purpose of studying the paranasal sinuses, thin sections should be used and both soft tissue and bone windows should be recorded. Our study indicates that in some normal infants development of a detectable maxillary sinus cavity may not occur until after birth. Caffey [9] noted that the small size of the maxillary sinuses in infants made interpretation of sinus radiographs difficult. He also felt that the opaque sinuses in infants under 10 months old were often due to redundant normal mucous membranes or to tears from crying. The cause of opacification of the antra of young infants is unclear, but in some cases, lack of development of a sinus cavity is the cause of a dense maxilla on sinus radiographs.

Conclusions

Our study suggests the following conclusions. (1) CT sinus abnormalities are not infrequently seen (18%) in children over 1 year old without signs or symptoms suggestive of sinusitis or URI. (2) Children with recent URI frequently (42%) have CT sinus abnormalities of uncertain origin but without clinical

manifestations of sinusitis. (3) Infants under 1 year old have high prevalence (72%) of CT sinus abnormalities with either soft-tissue-filled or underdeveloped sinus cavities. The prevalence of CT abnormalities is high, regardless of clinical findings. (4) Radiographic or CT sinus abnormalities in children should not be ascribed to sinusitis without appropriate clinical correlation, especially in infants under 1 year old.

ACKNOWLEDGMENT

We thank Major Wayne Pierson, USAF, MSC, for assistance with the statistical analysis of our data.

REFERENCES

1. Shopfner CE, Rossi JO. Roentgen evaluation of the paranasal sinuses in children. *AJR* **1973**;118:176-186
2. Schatz CJ, Becker TS. Normal CT anatomy of the paranasal sinuses. *Radiol Clin North Am* **1984**;22:107-118
3. Furukawa CT, Shapiro GG, Rachelefsky GS. Children with sinusitis. *Pediatrics* **1983**;71:133-134
4. Wald ER, Milmoie GJ, Bower A, Ledesma-Medina J, Salamon N, Bluestone CD. Acute maxillary sinusitis in children. *N Engl J Med* **1981**;304:749-754
5. Kogutt MS, Swischuk LE. Diagnosis of sinusitis in infants and children. *Pediatrics* **1973**;52:121-124
6. Kovatch AL, Wald ER, Ledesma-Medina J, Chiponis DM, Bedingfield B. Maxillary sinus radiographs in children with nonrespiratory complaints. *Pediatrics* **1984**;73:306-308
7. Maresch MM, Washburn AH. Paranasal sinuses from birth to late adolescence II. Clinical and roentgenographic evidence of infection. *Am J Dis Child* **1940**;60:841-861
8. Wald ER, Pang D, Milmoie GJ, Schramm VL. Sinusitis and its complications in the pediatric patient. *Pediatr Clin North Am* **1981**;28:777-796
9. Caffey J. *Pediatric x-ray diagnosis*. Chicago: Yearbook Medical Publishers, **1978**:111-118